

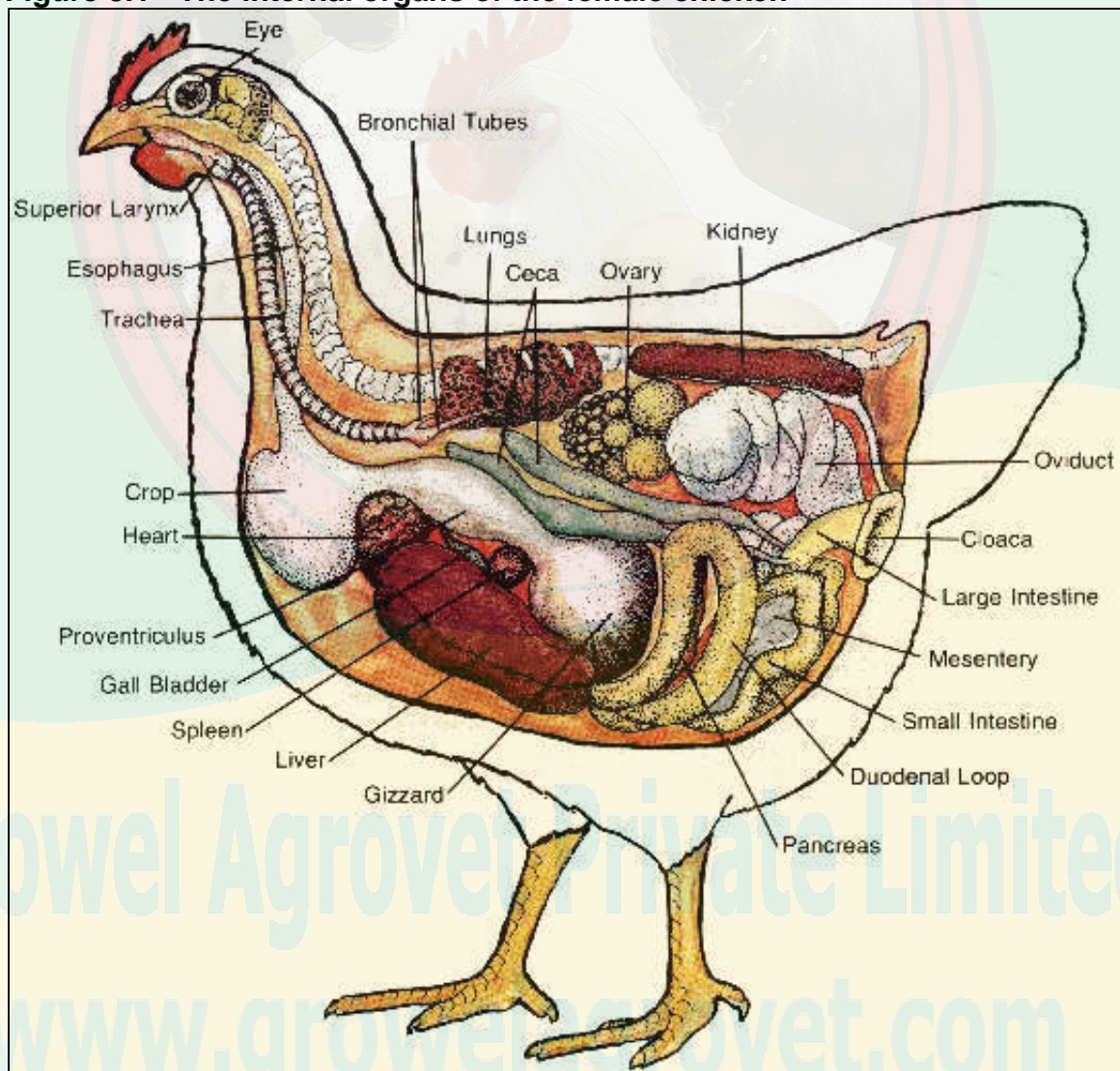
Chapter 3 - CHICKEN ANATOMY AND PHYSIOLOGY

Contents:

Digestive system	Reproductive system - male
Respiratory system	Circulatory system
Skeletal system	Nervous system
Muscle system	Excretory system
Reproductive system - female	Immune system

An overview of the internal organs of the female chicken is shown in Figure 3.1. A number of different systems are represented and they will be discussed individually.

Figure 3.1 - The internal organs of the female chicken

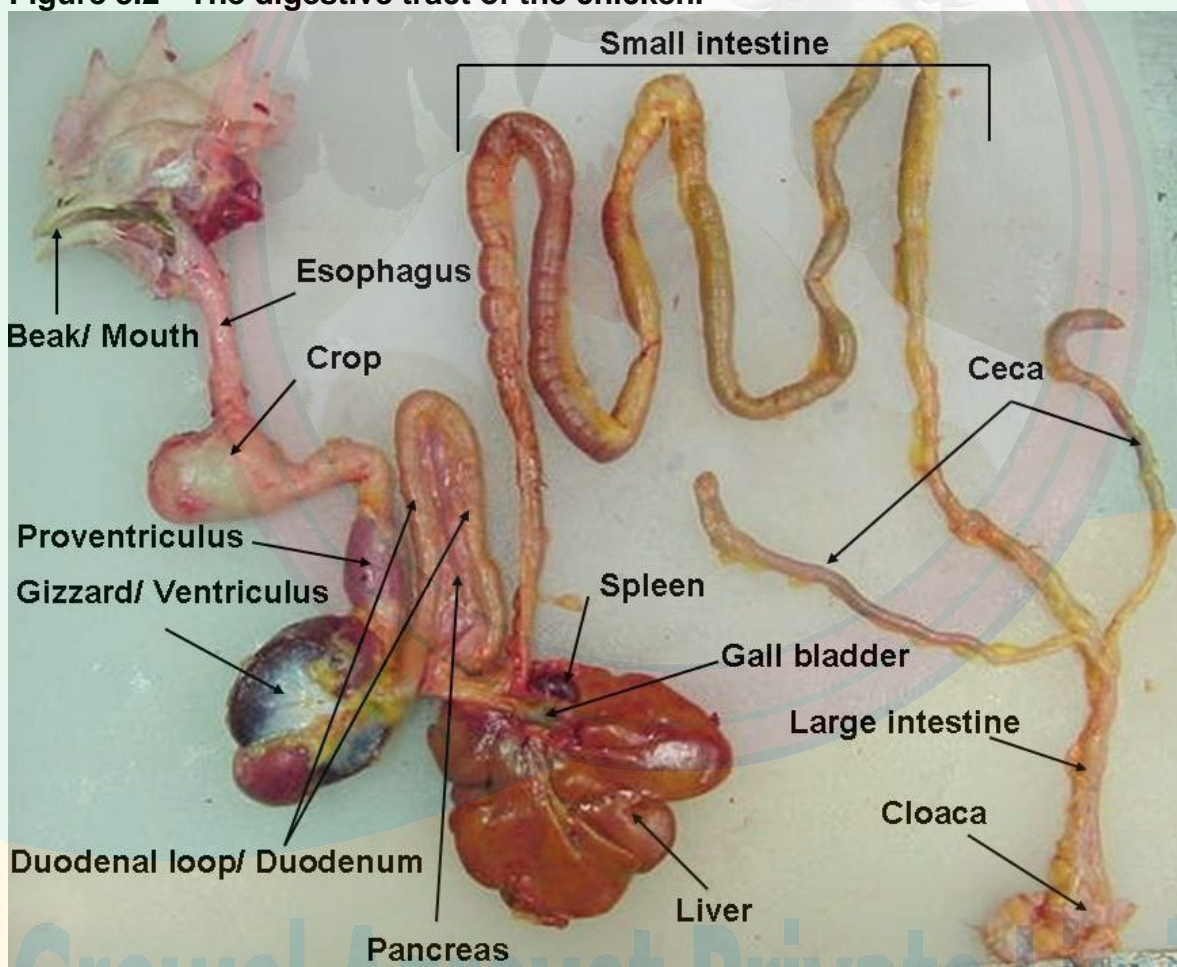


A. Digestive system

The digestive system uses the nutrients in consumed feed for the maintenance of all the other systems of the chicken's body. Ingested food is broken down to its basic components by mechanical and chemical means and these basic components are then absorbed and utilized throughout the body. A knowledge of the digestive process assists in understanding the nutritive requirements of chickens. In addition, knowing what's 'normal' can also help you recognize and take action when the digestive system goes awry. Frequent bouts with a particular digestive disorder, for example, may indicate a need for improved feeding or better sanitation.

The avian digestive system begins at the **mouth** and ends at the **cloaca** and has several intervening organs in between (see Figure 3.2).

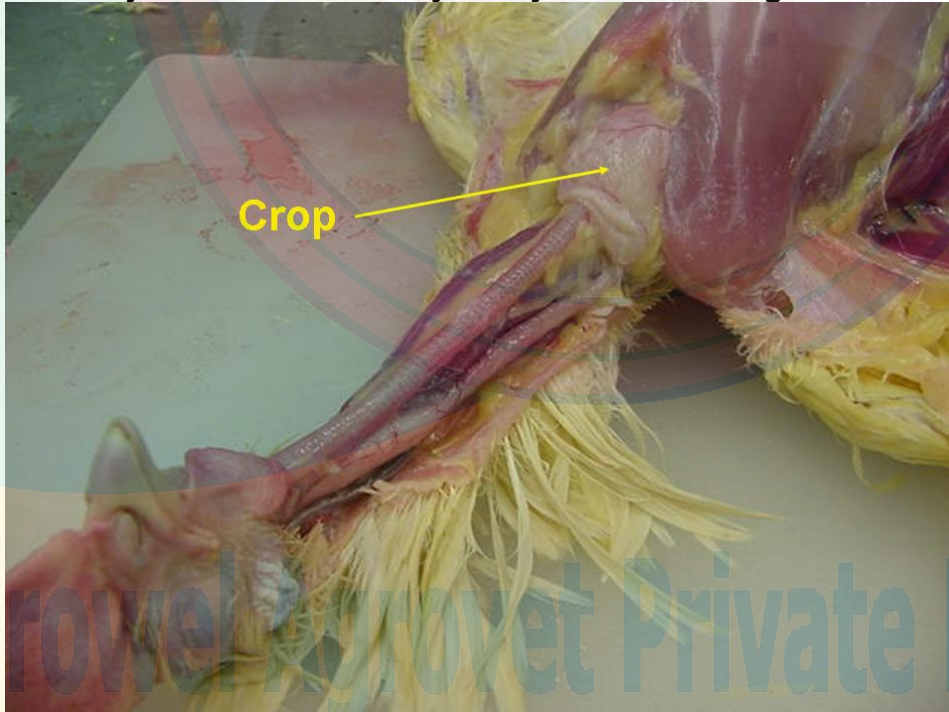
Figure 3.2 - The digestive tract of the chicken.



- **Beak / Mouth:** Chicken's obtain feed with the use of the beak. The feed then enters the digestive system via the mouth. The mouth contains glands that secrete saliva containing enzymes which begins the digestion of the feed consumed. The chicken does not have teeth to chew its feed. The **tongue** is used to push feed to the back of the mouth so that it can be swallowed. There are **taste buds** on the roof of the mouth and back of the tongue. The mouth is also very sensitive to temperature differences.

- **Esophagus:** The esophagus is a flexible tube that connects the mouth with the rest of the digestive tract. It carries food from the mouth to the crop and from the crop to the proventriculus.
- **Crop:** The crop is an out-pocketing of the esophagus and is located just outside the body cavity in the neck region (see Figure 3.3). Consumed feed and water are stored in the crop until the remainder of the digestive tract is ready to receive more feed. When empty, or nearly empty, the crop sends hunger signals to the brain so that more feed is consumed. Although the mouth excretes the digestive enzyme amylase, very little, if any, digestion takes place in the crop – it is simply a temporary storage pouch that evolved for prey birds which need to move to the open to feed. They are able to consume relatively large quantities of food rapidly and then return to a more secure location to digest it. Occasionally the crop becomes impacted (**crop impaction**, also referred to as **crop binding** or **pendulous crop**). This may occur when feed is withheld for a period of time, causing chickens to eat too much too fast when the feed is returned. A crop may also become impacted in a chicken that is free-ranged on a pasture of tough, fibrous vegetation. With a crop impaction, even if a chicken continues to eat, the feed can not get past the impacted crop. The swollen crop may also cut off the windpipe, suffocating the chicken. Crop impaction is unlikely to occur in properly fed broilers or broiler breeders.

Figure 3.3 - Photograph showing the location of the crop in a chicken. The crop is located just outside the body cavity in the neck region.



- **Proventriculus:** The esophagus connects the crop to the proventriculus. The proventriculus (also known as the '**true stomach**') is the **glandular stomach**

where digestion begins. As with our stomachs, hydrochloric acid and digestive enzymes (e.g., pepsin) are added to the feed here and digestion begins.

- **Gizzard / Ventriculus:** The gizzard is a unique part of the avian digestive tract and is often referred to as the '**mechanical stomach**'. It is made up of two sets of strong muscles which act as the bird's teeth. Consumed feed and the released digestive juices pass from the proventriculus to the gizzard for grinding, mixing, and mashing. Large poorly-soluble particles (such as small stones or grit) are retained in the gizzard until ground into tiny pieces by the action of the muscles and exposure to the acid and food particles. Broilers and broiler breeders fed only commercially prepared feed do not need grit. If, however, **whole grains** are fed without having access to grit, digestive efficiency will be impaired. When a chicken eats a small, sharp object such as a tack or staple, the object is likely to lodge in the gizzard, and due to the strong grinding motion of the gizzards muscles, may eventually pierce the gizzard wall. As a result, the chicken will grow thin and eventually die – a good reason to keep your poultry houses free of nails, glass shards, bits of wire and the like.
- **Small intestine:** The small intestine is made up of the duodenum (also referred to as the duodenal loop) and the lower small intestine. The **duodenum** receives digestive enzymes and bicarbonate (to counter the hydrochloric acid from the proventriculus) from the **pancreas** and bile from the **liver** via the **gall bladder**. The digestive enzymes produced by the pancreas are primarily involved in protein digestion. The pancreas plays important roles in both the digestive and hormonal systems. It also secretes hormones into the blood system that are important in the regulation of blood sugar. Bile is a detergent that is important in the digestion of lipids and absorption of fat-soluble vitamins (vitamins A, D, E and K). The remainder of the digestion occurs in the duodenum and the released nutrients are absorbed mainly in the **lower small intestine** (jejunum and ileum). The lower small intestine is composed of two parts, the jejunum and ileum. The meckel's diverticulum marks the end of the jejunum and the start of the ileum. Just prior to hatch, the yolk sac, which had been supplying nutrition during embryo development, is drawn into the navel cavity. The residual tiny sac is the meckel's diverticulum. The yolk sac supplies feed and water to the newly hatched chick and is the reason that chicks can be shipped considerable distances (as in the postal service) without adverse effects. **Omphalitis** is a condition characterized by infected yolk sacs, often accompanied by unhealed navels in recently hatched chicks. It is infectious but not contagious. It is often associated with excessive humidity and marked contamination of the hatching eggs or incubator. The affected chicks usually appear normal until a few hours before death. Depression, drooping of the head, and huddling near the heat source usually are the only signs. The navel may be inflamed and fail to close, producing a wet spot on the abdomen; a scab may be present.
- **Ceca (plural form; singular = cecum):** The ceca are two blind pouches at the junction of the small and large intestines. Re-absorption of water takes place in the ceca. Fermentation of coarse materials and production of the eight B vitamins (Thiamine, riboflavin, niacin, pantothenic acid, pyridoxine, biotin, folic acid and vitamin B₁₂) also occur in the ceca, but because the ceca are located near the

end of the digestive tract there is minimal absorption of any nutrients released. The ceca empty their contents two or three times a day, producing pasty droppings that often smell worse than regular droppings and often mustard to dark brown in color. The frequency of **cecal droppings**, as well as their appearance among regular droppings, tells you the chicken's digestive tract is functionally normally.

- **Large intestine (also known as the colon):** Despite the name, the large intestine is actually shorter than the small intestine. The large intestine is where the last of the water re-absorption occurs.
- **Cloaca:** In the cloaca there is a mixing of the digestive wastes together with wastes from the urinary system (urates). Fecal material is usually voided as digestive waste with white uric acid crystals on the outer surface (i.e., chickens do not urinate/pee). The reproductive tract also exits through this area (e.g., eggs or sperm).

Both the small and large intestine are normally populated by beneficial bacteria, referred to as **microflora** ('micro' meaning small and 'flora' meaning plants). Microflora aid in digestion and enhance immunity by guarding their territory (i.e., the digestive tract) against invading microbes. Intestinal disease normally occurs when the balance of microflora is upset or the normal microflora is overrun by too many foreign organisms. The result is **enteritis** or inflammation of the intestines, producing symptoms that include diarrhea, increased thirst, dehydration, loss of appetite, weakness, and weight loss or slow growth.

Chicken Feces

The color and texture of chicken fecal material can indicate the health status of the chicken's digestive tract. The white pasty material that commonly coats chicken fecal material is **uric acid**, the avian form of urine, and is normal (see Figure 3.4).

Figure 3.4 - Normal chicken manure



Some of the possible abnormal color and texture changes that can occur, together with possible causes, are shown below. These are just possible causes and not a definite cause. If you notice any abnormalities, notify your service person as soon as possible.

Appearance of Feces

- Droppings with blood = coccidiosis
- Greenish droppings = late stages of worms (or has eaten a lot of green vegetables if free-ranged)
- White, milky runny droppings = worms, coccidiosis, Gumboro disease (Infectious Bursal Disease)
- Brown runny droppings = *E. coli* infection
- Clear or watery runny droppings = stress, Infectious Bronchitis
- Yellow & foamy droppings = coccidiosis
- Grayish white & running continuously = vent gleet (a chronic disease of the cloaca of domestic birds)

B. Respiratory system

The respiratory system is involved in the absorption of oxygen, release of carbon dioxide, release of heat (temperature regulation), detoxification of certain chemicals, rapid adjustments of acid-base balance, and vocalization. While the function of the avian respiratory system is comparable to that of mammals, the two are quite different anatomically. Birds don't breathe the same way mammals do. Like mammals, birds have two symmetrical lungs that are connected to a **trachea** (windpipe). But here the similarity ends. Mammalian lungs contain many bronchi (tubes), which lead to small sacs called alveoli. Because alveoli have only one opening, air can flow into and out of them, but it can not flow through them to the outside of a lung. In comparison, the avian lung has parabronchi which are continuous tubes allowing air to pass through the lung in one direction. They are laced with blood capillaries and it is here that gas exchange occurs.

The trachea divides into two smaller tubes called **bronchi** (plural form; singular = bronchus). In some respiratory diseases **tracheal 'plugs'** are often formed and they physically block the respiratory tract at the junction of the bronchi. As a result, the chickens suffocate. Excessive dust in the air is also believed to result in the formation of caseous tracheal plugs and adversely affect the health of the chickens.

The avian respiratory tract (Figures 3.5 and 3.6) starts with the **glottis** which closes when feed is passing down the throat so that feed does not enter the lungs. The **trachea** is made up of cartilaginous rings that prevent its collapse from the negative pressure caused by inspiration of air. The **syrix** is the voice box. The chicken 'voice' is produced by air pressure on a sound valve and modified by muscle tension. It is not possible to remove the syrix to prevent roosters from crowing. Both roosters and hens are able to 'crow.' The reason hens don't normally crow is because they 'don't feel like it' due to female hormone effects and the absence of sufficient levels of the male hormone. When the ovaries become diseased and the level of female hormones decrease, many hens will start to show male characteristics, including crowing.

Figure 3.5 – Illustration showing the parts of the avian respiratory tract.

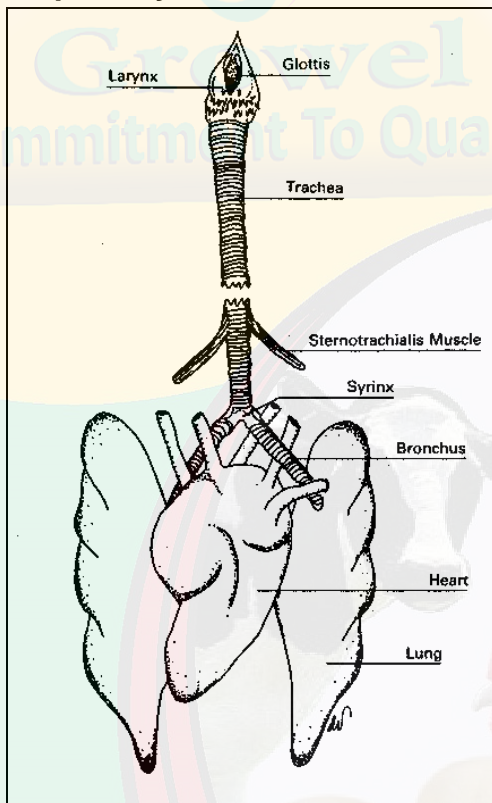
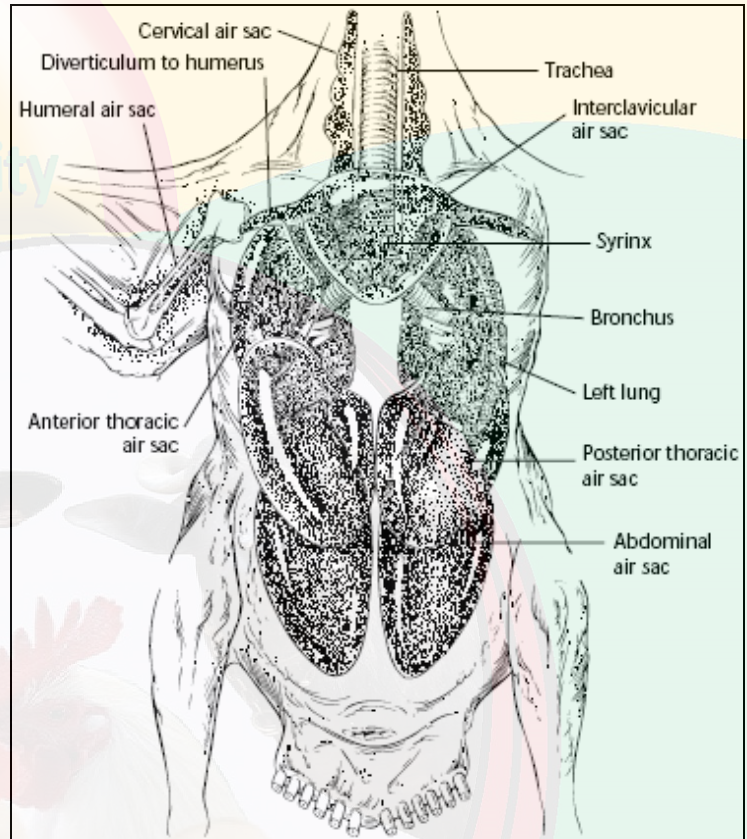



Figure 3.6 - Illustration showing the location of the avian air sacs.



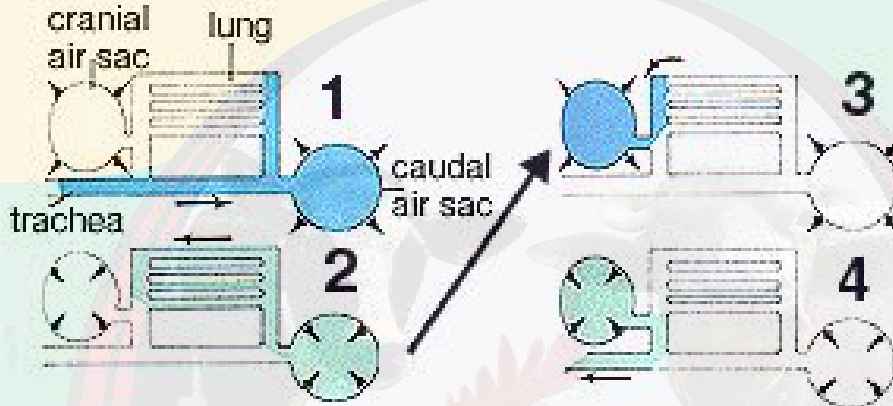
The **lungs** are relatively small and do not expand. Instead, they are firmly attached to ribs. Birds have an **incomplete diaphragm** and the arrangements of the chest musculature and the sternum do not lend themselves to expansion in the same way that the chest of mammals does. Consequently they can't inflate and deflate lungs in the same way as mammals do. Instead, birds pass air through the lungs by means of **air sacs**, a uniquely avian anatomical feature. The air sacs are balloon-like structures at the 'ends' of the airway system. In the chicken there are nine such sacs: an unpaired one in the cervical region; two interclavicular air sacs, two abdominal air sacs, two anterior thoracic air sacs and two posterior thoracic air sacs (see Figure 3.7). The avian respiratory system is described as **non-tidal**. The mammalian respiratory system, in contrast, is tidal.

Figure 3.7 - Dorsal view of the air sac locations in chickens



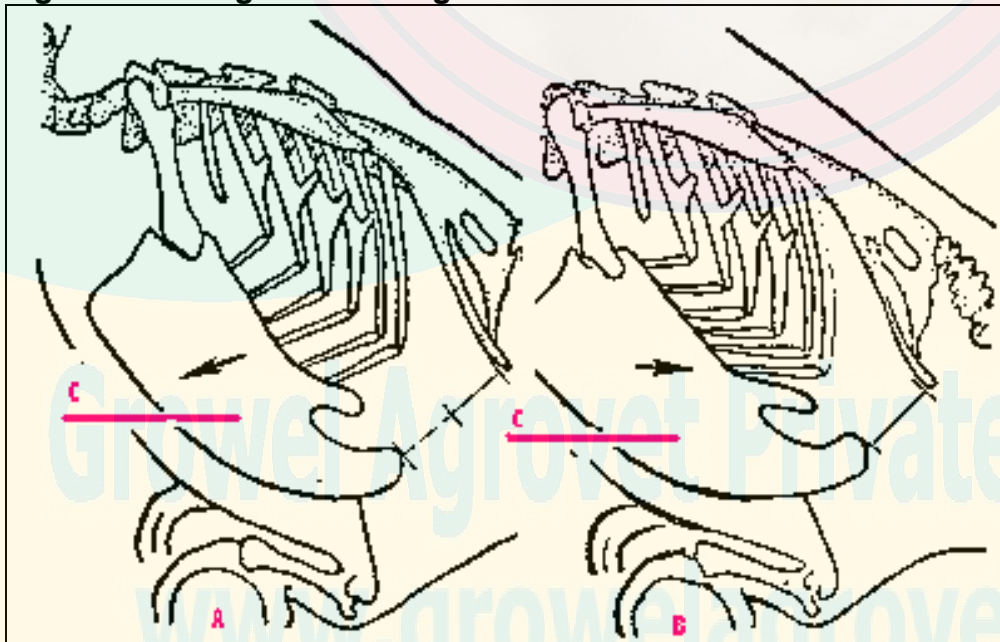
The key to the avian respiratory system is that distention and compression of the air sacs, not the lungs, moves air in and out. At any given moment air may be flowing into and out of the lung and being 'parked' in the air sacs (see Figure 3.8). The lungs are stiff and fixed, not at all like the distensible lungs of mammals. The air sacs act as 'bellows' to suck air in and blow it out and also to hold part of the total volume. The air sacs fill a large proportion of the chest and abdominal cavity of birds, and also connect to the air spaces in the bones.

Figure 3.8 - The flow of air through the avian respiratory system.



1. **On first inhalation**, air flows through the trachea & bronchi, primarily into the posterior (rear) air sacs
2. **On exhalation**, air moves from the posterior air sacs into the lungs
3. **With the second inhalation**, air moves from the lungs into the anterior (front) air sacs
4. **With the second exhalation**, air moves from the anterior air sacs back into the trachea and then out

Figure 3.9 - Diagram showing movement of sternum and ribs during respiration



A. Inspiration; B. Expiration; C. Sternum (keel)

Since birds do not have a diaphragm, they depend on the movement of the sternum (keel) and rib cage in order to breathe (see Figure 3.9). Holding a bird too tight will restrict movement of the rib cage and suffocate the bird. This often happens when young children hold baby chicks.

With each breath, the chicken's respiratory tract is exposed to the inside environment of a poultry house. Poor environments normally do not cause disease directly but they do reduce chickens' defenses, making them more susceptible to existing viruses and pathogens.

The air of poultry houses can contain **aerosol particles** or 'dust' originating from the floor litter, feed, dried manure, and the skin and feathers of the chickens. These aerosol particles can have a range of adverse effects on poultry. They act as an irritant to the respiratory system and coughing is a physiological response designed to remove them. Excessive coughing lowers the chicken's resistance to disease. Aerosol particles often collect inside the chicken and can increase carcass condemnation at the processing plant.

The chicken's respiratory tract is normally equipped with defense mechanisms to prevent or limit infection by airborne disease agents; to remove inhaled particles; and to keep the airways clean. Chicken health is affected by the function of three defensive elements: the cilia; the mucus secretions; and the presence of scavenging cells which consume bacteria.

Cilia are tiny hair-like structures in the trachea. Cilia are responsible for propelling the entrapped particles for disposal. **Mucus** is produced in the trachea. Mucus secretion and movement of cilia are well developed in chickens. The consistency of the mucus produced is important for the efficiency of the ciliary activity. Cilia cannot function when the mucus is too thick.

Scavenging cells in the lungs actively 'scavenge' inhaled particles and bacteria that gain entrance to the lower respiratory tract. These cells consume bacteria and kill them, thus preventing their further spread.

It is the integrated function of cilia, mucus and scavenging cells that keeps broiler airways free of disease-producing organisms. The impairment of even one of these components permits an accumulation of disease agents in the respiratory tract and may result in disease.

Gases are generated from decomposing poultry waste; emissions from the chickens; and from improperly maintained or installed equipment, such as gas burners. Harmful gases most often found in poultry housing are ammonia (NH₃) and carbon dioxide (CO₂). Research has shown that as little as 10 ppm ammonia will cause excessive mucus production and damage to the cilia. Research has also revealed that ammonia levels of 10-40 ppm reduce the clearance of *E. coli* from air sacs, lungs, and tracheas in chickens.

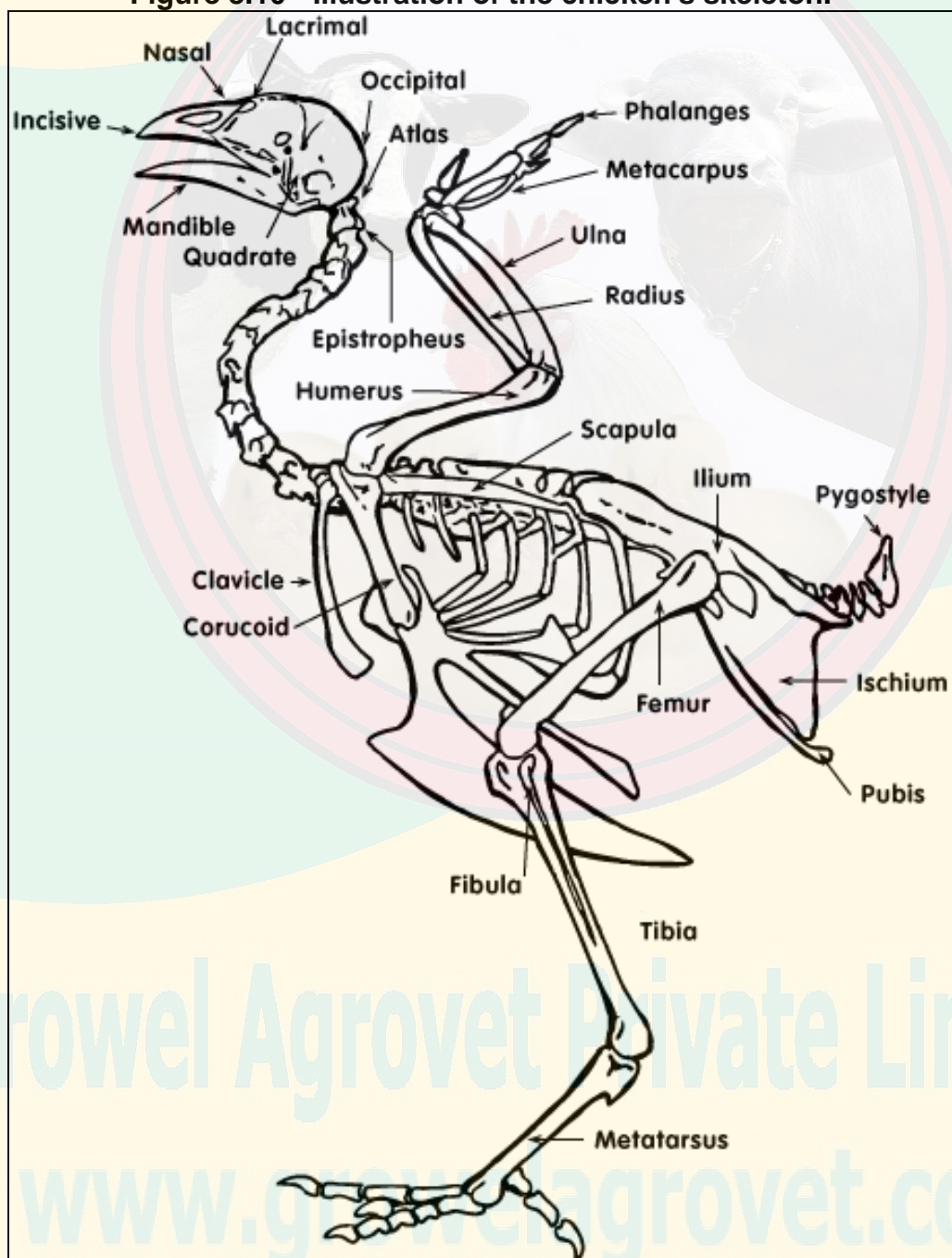
www.growelagrovvet.com

C. Skeletal system

Aside from the obvious role of **structural support**, the skeletal system (see Figure 3.10) has two additional functions: **respiration** and **calcium transport**.

The skeletal system of the bird is compact and lightweight, yet strong. The tail and neck vertebrae are movable, but the body vertebrae are fused together to give the body sufficient strength to support the wings. There are two special types of bones which make up the bird's skeletal system: the pneumatic and medullary bones.

Figure 3.10 - Illustration of the chicken's skeleton.



The **pneumatic bones** are important to the chicken for respiration. They are hollow bones which are connected to the chicken's respiratory system and are important for the chicken to breathe. Examples of pneumatic bones are the skull, humerus, clavicle, keel (sternum), pelvic girdle, and the lumbar and sacral vertebrae.

The **medullary bones** are an important source of **calcium** for the laying hen. Calcium is the primary component of egg shell and a hen mobilizes 47% of her body calcium to make the egg shell. Examples of medullary bones are the tibia, femur, pubic bones, ribs, ulna, toes, and scapula.

D. Muscle system

There are three types of muscles in the chicken's body: smooth, cardiac, and skeletal. **Smooth muscle** is controlled by the **autonomic nervous system** (ANS) and is found in the blood vessels, gizzard, intestines and organs. The **cardiac muscle** is the specialized muscle of the heart. The **skeletal muscle** is the type of muscle responsible for the shape of the bird and for its voluntary movement. This is the muscle type that makes up the edible portions of the carcass. The most valuable skeletal muscles in a poultry carcass are the breast, thigh and leg.

The breast meat is referred to as '**white meat**'. White meat is 'white' because of a lower level of exercise for these muscles. The thigh and leg meat are referred to as '**dark meat**.' Dark meat is 'dark' because the muscles are used for sustained activity – in the case of a chicken, chiefly walking. The dark color comes from a chemical compound in the muscle called **myoglobin**, which plays a key role in oxygen transport. White muscle, in contrast, is suitable only for short, ineffectual bursts of activity such as, for chickens, flying. That's why the chicken's leg meat and thigh meat are dark and its breast meat (which makes up the primary flight muscles) is white. Other species of poultry more capable of flight (such as ducks, geese, and guinea fowl) have dark meat throughout.

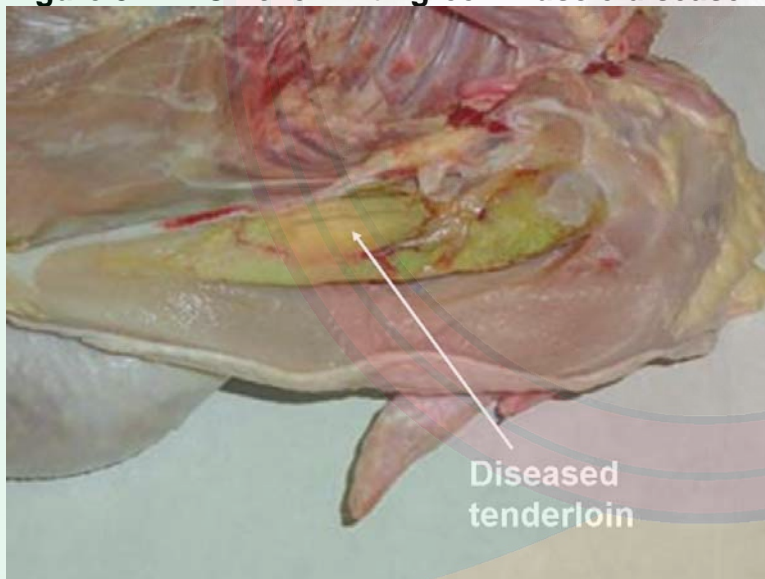
The main objective of the broiler industry is the production of **SALEABLE chicken meat**. To this end, it is important to limit to a minimum the number of condemnations at the processing plant and to maximize meat yield. Production of a quality meat product from a live broiler chicken involves a series of efficiently-performed, specific tasks carried out in a sanitary manner. Before broilers can be processed they must be raised to market age, caught, cooped, transported and held; then unloaded at the processing plant. Inside the processing plant, broilers are hung on shackles, stunned, bled, de-feathered, eviscerated, inspected, chilled, graded, and packaged. Because of the complexity of production and processing procedures, several factors may reduce carcass yield and adversely affect carcass grade. Defects resulting in carcass downgrading and product losses are caused by disease, damage to the chicken before slaughter, or maladjusted equipment and manual errors during processing.

Good live haul procedures can reduce bruising and the number of DOAs (dead on arrivals). Broilers that are transported long distances (6+ hours) have fewer bruises due to confinement, and the fatigue from traveling makes them less active during slaughter. However, the stress associated with transporting slows digestive tract clearance and increases the **live shrink** (live weight loss).

With regard to meat quality, the poultry industry has seen an increase in the occurrence of **Pale Soft and Exudative (PSE)** meat over the past several years. PSE meat is the result of accelerated postmortem glycolysis, which results in a rapid pH decline while carcass temperatures are still high. Processors are concerned with the appearance of **PSE meat** in fresh tray packs as the pale color can affect color uniformity within the package. Although pale meat is still healthy, it is less pleasing to the customer. All poultry meat loses moisture, but pale meat loses slightly more. Pale meat is estimated to result in an annual loss of about \$200 million for the U.S. broiler industry.

Another meat quality concern is **Green Muscle Disease** or Deep Pectoral Myopathy (see Figure 3.11), which is the necrosis of the Pectoralis Minor (tender) muscle of poultry. Necrotic tenders appear yellowish-green in color. Green Muscle Disease results from vigorous activity of both major and minor pectoralis muscles, but only the tenders are afflicted. During contraction, muscles normally swell with increased blood flow to supply needed oxygen and nutrients. Compared to other muscles, the tenders have a more rigid muscle cover and are confined to a tight space within the body such that they can't expand to accommodate this increased blood flow. The net result of the muscle being confined and compressed is self strangulation, suffocation, and eventually necrosis.

Figure 3.11 - Chicken with green muscle disease



The incidence of Green Muscle Disease increases with higher market weight in broilers, and more cases are reported in higher yielding crosses and in males. Increased broiler activity induced by such factors as feed or water outages, lighting programs, catching and live haul, and even excessive noise, may result in an increased incidence of Green Muscle Disease. The increased activity associated with free-range broiler production has resulted in an increased incidence of Green Muscle Disease in this industry.

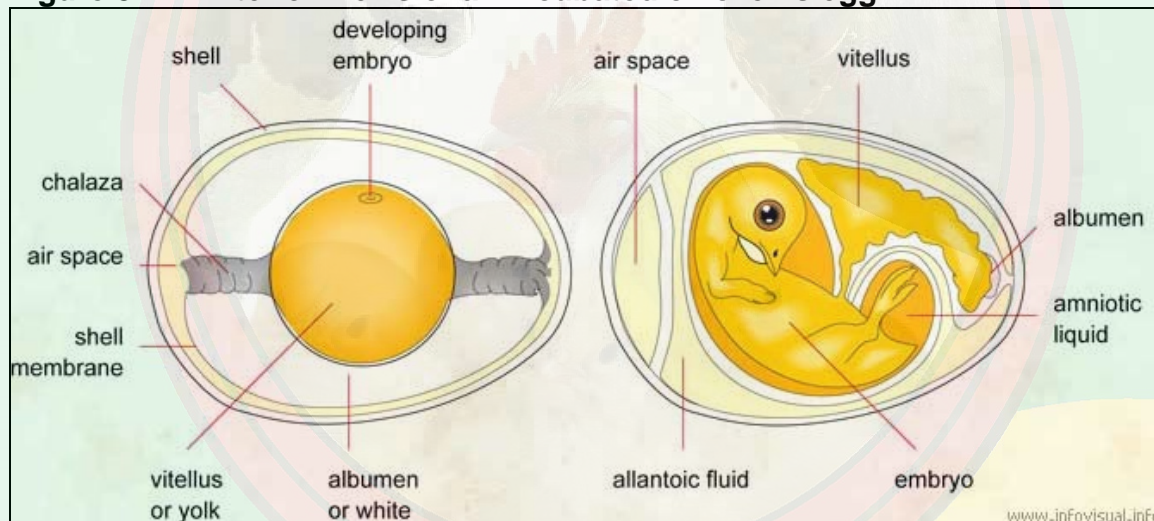
www.growelagrovvet.com

E. Reproductive system - female

The avian reproductive system is very different from that of mammals and is better suited to the peculiar hazards of being a bird. The biggest problem with being a bird is that everyone is trying to eat you. While most mammals (especially primates) have adopted a strategy of having relatively few offspring and devoting a fair amount of parental energy and time to caring for those few, most birds (with some notable exceptions) have gone the other way: they produce lots of offspring, give them some minimal amount of raising – in some cases, none – then toss them to the winds, literally and figuratively. The parts of an incubated egg are shown in Figure 3.12.

The female reproductive system of the chicken (Figure 3.13) is divided into two main parts: the ovary and the oviduct. In the majority of avian species, including chickens, only the left ovary and oviduct are functional. Although the right is present embryologically, it regresses during development and is vestigial in the adult bird.

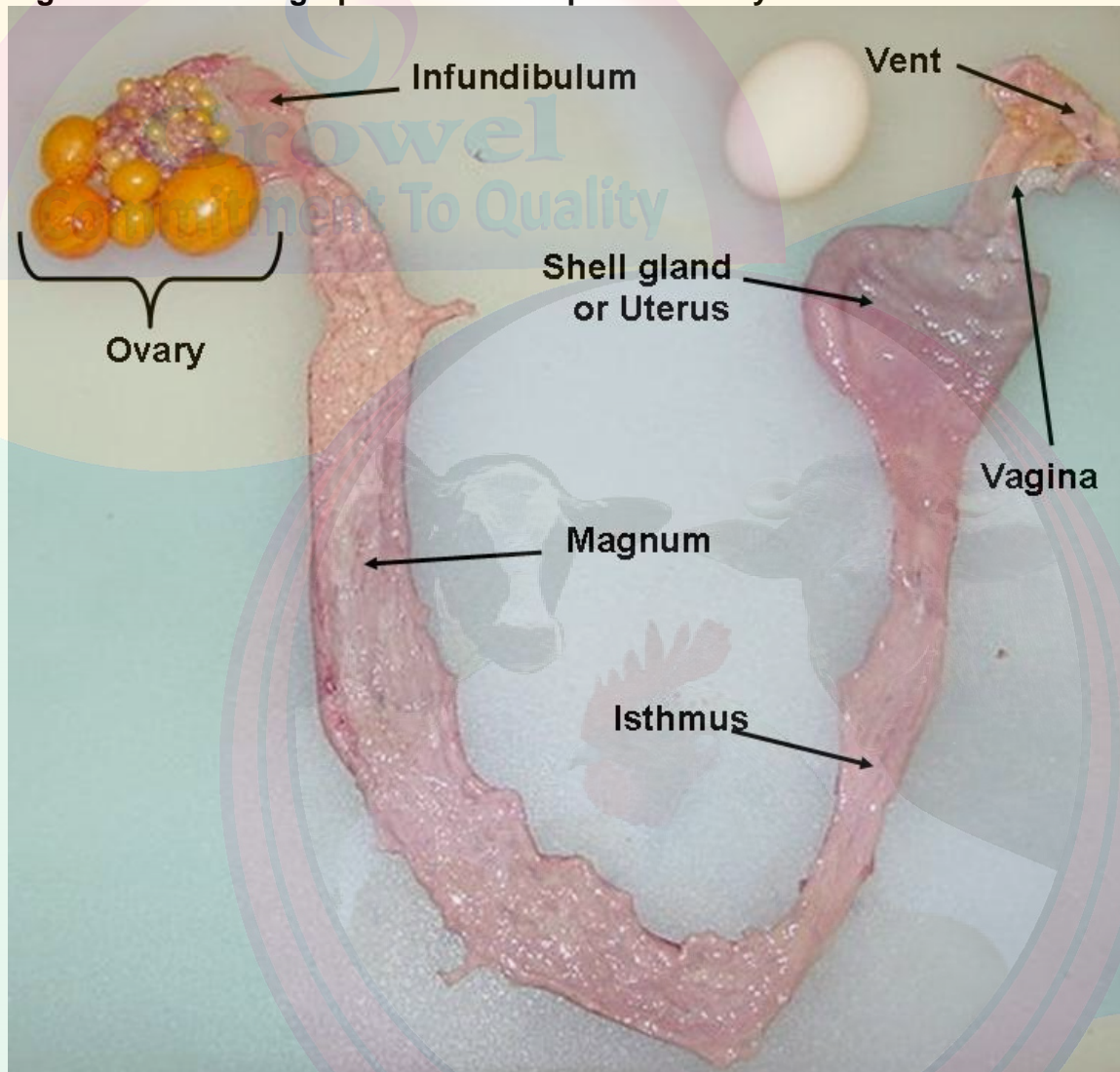
Figure 3.12 - Interior views of an incubated chicken's egg.



The **ovary** is a cluster of developing yolks or **ova** and is located midway between the neck and tail of the bird, attached to the back. The ovary is fully formed although very small when the female chick is hatched. It is made up of 13,000 – 14,000 ova which grow by the addition of yolk fluid. Each ovum (singular of ova) starts out as a single cell surrounded by a **vitelline membrane**. As the ovum develops, yolk is added. The color of the yolk comes from fat soluble pigments called **xanthophylls** contained in the hen's diet. At hatch, chicks (like codfish and mammals) are equipped with tens of thousands of potential eggs which theoretically *could* be laid, but (as with the oocytes of mammals) most of them never develop to the point of ovulation. No new ova are produced once the chick has hatched.

Ovulation is the release of the mature ovum from the ovary into the second part of the female reproductive system, the oviduct. The ovum, which is enclosed in a sac, ruptures along the suture line or **stigma**. This release of the ova occurs 30-75 minutes after the previous egg has been laid.

Figure 3.13 - Photograph of a hen's reproductive system.



The second major part of the female chicken's reproductive system is the **oviduct**. The oviduct is a long convoluted tube (25-27 inches long when fully developed) which is divided into five major sections. They are the infundibulum or funnel, magnum, isthmus, shell gland, and vagina.

The first part of the oviduct, the **infundibulum** or funnel, is 3-4 inches long, and it engulfs the ovum released from the ovary. The ovum or yolk remains in the infundibulum 15-18 minutes. The infundibulum also serves as a reservoir for spermatozoa so that **fertilization** can take place.

The next section of the oviduct is the **magnum** which is 13 inches long and is the largest section of the oviduct as its name implies (from the Latin word for 'large'). The ovum or yolk remains here 3 hours during which time the thick white or **albumen** is added.

The third section of the oviduct is the **isthmus** which is 4 inches long. The 'egg' remains here for 75 minutes. The isthmus, as its name implies, is slightly constricted (The term

'isthmus' refers to a narrow band of tissue connecting two larger parts of an anatomical structure). The isthmus is where the inner and outer **shell membranes** are added.

The next section of the oviduct is the **shell gland** or uterus. The shell gland is 4-5 inches long, and the 'egg' remains here for 20 plus hours. As its name implies, the **shell** is placed on the egg here. The shell is largely made up of calcium carbonate. The hen mobilizes 47% of her body calcium from her bones to make the egg shell, with the diet providing the remainder of the required calcium. Pigment deposition is also done in the shell gland.

The last part of the oviduct is the **vagina** which is about 4-5 inches long and does not really play a part in egg formation. The vagina is made of muscle which helps push the egg out of the hen's body. There are also glands located in the vagina where spermatozoa are stored. The **bloom** or cuticle is also added to the egg in the vagina prior to oviposition (the laying of the fully formed egg).

Near the junction of the vagina and the shell gland, there are deep glands lined with simple columnar epithelium. These are the **sperm host glands**, so called because they can store sperm for long periods of time (10 days to 2 weeks!). When an egg is laid, some of these sperm can be squeezed out of the glands into the lumen of the tract, so that they can migrate farther up the oviduct to fertilize another egg. This is one of the really remarkable things about birds; ***the sperm remain viable at body temperature.***

Birds lay eggs in clutches. A **clutch** consists of one or more eggs, followed by a rest period of about a day, then another egg or set of eggs. Clutch size is species-specific and is held within fairly tight limits. Clutch size, as well as the numbers of clutches laid in a breeding season, will vary with species, but the principle is the same.

In hens, ovulation usually occurs in the morning and under normal daylight conditions, almost never after 3:00 PM. The total time to form a new egg is about 25-26 hours. This includes about 3½ hours to make the albumen, 1½ hours for the shell membranes, and about 20 hours for the shell itself.

Ovulation for the next egg of a clutch occurs within an hour of laying the previous egg, and so that each day the hen gets later and later in her timing; she "runs behind," like a clock that is improperly adjusted. Eventually she gets so far behind schedule that she would have to ovulate later than 3:00 PM. Since hens do not typically ovulate after 3:00 PM, the next ovulation is delayed and egg laying is interrupted. This delay results in the break between clutches and the cycle repeats itself a day or so later.

Occasionally, a hen will produce **double-yolked eggs**. This phenomenon occurs primarily due to the age of the hen, but can also be related to genetics. Young hens sometimes release two follicles from the ovary in quick succession. The highly active ovary due to high activity of reproductive hormones in peak egg production can also be a factor. Double-yolked eggs are larger in size than single yolk eggs. Double-yolked eggs are not suitable for hatching. There is typically not enough nutrients and space available for two chicks to develop to hatch. It has happened, but it is rare.

Occasionally an egg contains more than two yolks. The Guinness Book of Records lists the world's largest chicken egg (with a diameter of 9 inches or 22.5 cm) as having five yolks and the heaviest egg (1 pound or 0.45 kg) as having a double yolk and a double shell.

It is rare, but not unusual, for a young hen to produce an egg with no yolk at all. **Yolkless eggs** are usually formed when a bit of tissue is sloughed off the ovary or oviduct. This tissue stimulates the secreting glands of the different parts of the oviduct and a yolkless egg results.

Things occasionally go wrong when an egg shell is being developed. The most obvious relates to shell texture (Figure 3.14). Occasionally the shell becomes damaged while still in the shell gland and is repaired prior to being laid. This results in what is known as a '**body check**.' Occasionally there will be '**thin spots**' in the shell or '**ridges**' will form. The shells of such eggs, though not cracked, are weaker than 'normal' eggs and should not be used as hatching eggs. A second category of problems is **abnormal shape** (Figure 3.15). To be considered a hatching egg, the egg should be the typical 'egg shape.' Abnormally shaped eggs should not be used as hatching eggs. In many cases it is not clear which is the large end (and eggs should be incubated large end up) or they may not properly fit in the egg trays.

Occasionally an egg will be laid without a shell. It feels like a water balloon. The membrane was placed on the yolk and white, but it somehow slipped past the "shell mechanism" and the shell wasn't deposited. The occurrence of the occasional shell-less egg is not necessarily an indication of any disease problem. If the incidence increases, however, a veterinarian should be consulted.

Even rarer is an egg within an egg. This occurs when an egg that is nearly ready to be laid reverses direction and gets a new layer of albumen covered by a second shell. Sometimes the reversed egg joins up with the next egg and the two are encased together within a new shell. Double shelled eggs are so rare that no one knows exactly why or how they happen.

Figure 3.14 - Examples of poor exterior egg quality related to shell texture.

A. Body check



B. Thin spot



C. Ridges



www.growelagrovvet.com

Figure 3.15 - Examples of abnormally shaped eggs.

A. Pear-shaped egg



B. Football-shaped egg



F. Reproductive system - male

The avian male reproductive system (Figures 3.16 and 3.17) is all inside the bird – unlike mammals which have the testes outside of the body. The male chicken possesses two **testes**, along the back, near the anterior ends of the kidneys. They are elliptical shaped and light yellow in color. Each **ductus deferens** opens into a small bump, or **papilla**, which is on the dorsal wall of the cloaca. The papillae serve as the copulatory organ. The incorrectly named, "**rudimentary copulatory organ**" is located on the medial ventral portion of the cloaca and is used to classify the sex of baby chicks.

Figure 3.16 - Diagram of the avian male reproductive tract

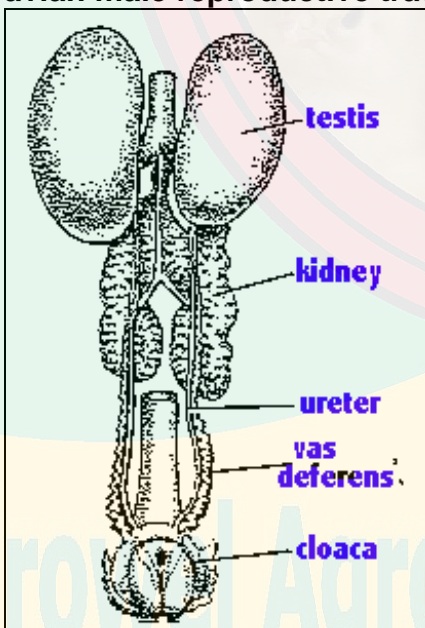
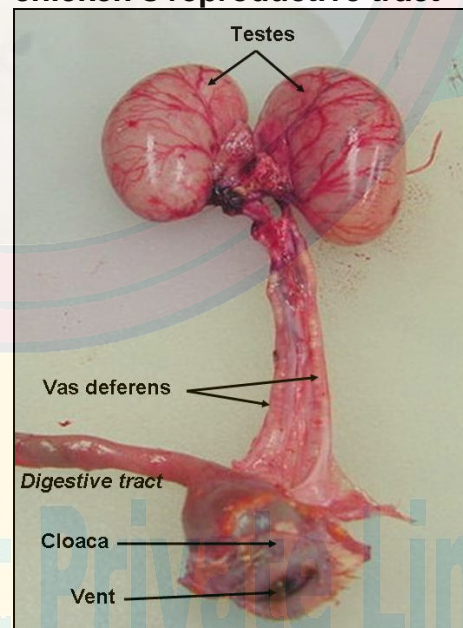


Figure 3.17 - Photo of a male chicken's reproductive tract



The main goal of broiler breeder management is to produce **hatching eggs**. However, the only good hatching egg is a fertilized egg. **Fertility**, the percentage of eggs laid that are fertilized, is very important in hatching egg production. If an egg is not fertilized, then,

of course, it will not contain an embryo and will not hatch. Simply put, "Hatchability can never be better than fertility."

Fertility is affected by both the male and the female, and both tend to decline as the chickens age. Flock fertility is dependent on the reproductive status of the chickens (i.e., level of egg and semen production) combined with the chickens' interest and capability of mating. The fertility of a broiler breeder flock usually increases from a low of 65-75% at the start of lay (23-24 weeks of age) and peaks at 95-98% at 35-37 weeks of age. Between 40-45 weeks of age fertility declines and the older the birds get the faster the decline in fertility. From the female side, the decline in fertility is believed to be due to faster release of sperm from the sperm storage tubules. As a result, after 40 weeks of age the breeder hen needs more frequent mating to sustain high fertility. From the male side it is presumed that there is a decrease in sperm quality as the rooster ages, as well as a decrease in mating activity. There is also believed to be an increase in early embryo death in the second half of the reproduction cycle. These early deaths often appear as 'clears' and may be mistaken for infertiles.

Walking through the supermarket, it is often possible to find **capons** for sale. While it is obvious from the shape of the packaging that it is a bird of some kind, there is often no indication in the labeling of what exactly a capon is. An informal survey of 4-Hers with poultry projects and university students very few knew what a capon is. In **caponization**, the surgical castration of male chickens, the testes of the male chicken are completely removed. As a result, the cockerel fails to develop certain male characteristics or tends to lose them if they are developed. Capons are usually quiet and docile, lacking a cockerel's disposition to fight. The comb and wattles cease growing after castration, so the head of a capon looks small. The hackle, tail and saddle feathers grow unusually long.

Removal of the testes, and thus elimination of the male sex hormones they produce, reduces the male sex instinct and changes their behavior. They will become more docile and less active. Energy that is normally expended in fighting, courting behavior, and territorial protection is greatly reduced, allowing more efficient conversion of feed into growth, fat deposition and improved meat quality.

Caponizing produces a unique type of poultry meat grown for a specialized market. The meat of uncastrated cockerels tends to become rather coarse, stringy, and tough as the chickens age. This is not the case with the capon. Caponized males grow more slowly than normal male chickens and accumulate more body fat. The concentration of fat in both the light and dark meat of capons is greater than that of intact males. It is claimed that the capon meat is more tender, juicier, and more flavorful than regular chicken.

Any breed of chicken can be caponized. Over the past 100 years breeds that were particularly favored for capon production included Jersey Giants, Brahmas, Orpingtons, Cornish, Plymouth Rocks, and Cochins. Today commercially grown capons are produced using the Cornish x Plymouth Rock cross typically used by the commercial broiler industry. Male birds are typically caponized at two to four weeks of age. The testes of a male chicken are located within the abdominal cavity. A good caponizer can operate on about 200 birds per hour. Commercially grown capons are marketed at 15 to

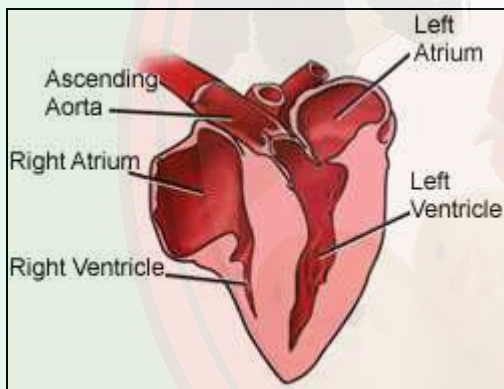
18 weeks of age. The goal is a capon weighing six to eight pounds at packaging (9 to 11 pounds live weight).

Today, relatively few capons are marketed commercially in the United States. It is estimated that around a million capons are produced annually. This is in contrast with the 8 billion broilers produced each year. Today commercial capon production in the United States is now limited to a single producer, Wapsie Produce Company in Iowa.

G. Circulatory system

The avian circulatory system consists of a heart plus vessels that transport nutrients, oxygen and carbon dioxide, waste products, hormones, and heat. The vascular system of birds differs from that of mammals in that there is an additional renal portal system. Venous blood from the legs flows directly to the kidneys and further to the posterior vena cava.

Figure 3.18 - Diagram of the avian heart.



Birds, like mammals, have a **4-chambered heart** (Figure 3.16), with complete separation of oxygenated and de-oxygenated blood. The right ventricle pumps blood to the lungs, while the left ventricle pumps blood to the rest of the body. Because the left ventricle must generate greater pressure to pump blood throughout the body (in contrast to the right ventricle that pumps blood to the lungs), the walls of the left ventricle are much thicker & more muscular.

Birds tend to have **larger hearts** than mammals (relative to body size and mass). The relatively large hearts of birds may be necessary to meet the high metabolic demands of flight. Among birds, smaller birds have relatively larger hearts (again relative to body mass) than larger birds. Hummingbirds, for example, have the largest hearts (relative to body mass) of all birds, probably because hovering takes so much energy.

Avian hearts also tend to **pump more blood** per unit time than mammalian hearts. In other words, cardiac output (amount of blood pumped per minute) for birds is typically greater than that for mammals of the same body mass. Cardiac output is influenced by both heart rate (beats per minute) and stroke volume (blood pumped with each beat). 'Active' birds increase cardiac output primarily by increasing heart rate.

The **red and white blood cells** are formed in the **spleen**. A bird's red blood cells are unique in that they are nucleated (there is a nucleus) whereas a mammal's are not.

Significant diseases of the cardiovascular system in poultry meat inspection include pericarditis and ascites. **Pericarditis** is an inflammation of the fibroserous membranous sac called pericardium, which encloses and lubricates the heart. **Ascites** is an increase of fluid in one or more of the abdominal spaces.

Broilers subject to high environmental temperatures exhibit many behavioral changes which allow them to re-establish **heat balance** with their surrounds. They tend to rest more or will position themselves close to walls or waterers. They spread their wings away from the body to promote cooling by reducing body insulation. Within the bird, blood is diverted from certain internal body organs such as the liver, kidneys and intestines to dilated blood vessels of the peripheral tissue (i.e., skin) in order to facilitate heat loss.

As ambient air temperatures increase past 85°F, chickens respond by trying to lose more heat through evaporative cooling which is accomplished by panting. However, this process also generates more heat through the muscular activity involved in panting. Normally blood pH is controlled by the lungs and kidneys along with the various buffer systems which prevent rapid changes in the pH. As the respiratory rate increases in heat stressed broilers, however, there is also a corresponding decrease in the levels of blood carbon dioxide. **Respiratory alkalosis** (i.e., elevated blood pH) results as the blood acid-base balance is disrupted. This produces a decrease in blood calcium and bicarbonate which are necessary for the production of strong egg shells. Thus, the ultimate problem with broiler breeders is a production of thin-shelled eggs produced by laying hens. As for growing chickens, heat stress affects them by depressing weight gain mainly because feed intake is depressed.

H. Nervous system

The nervous system is divided into two main parts which are the **central nervous system** (CNS) and the **autonomic nervous system** (ANS). The CNS is responsible for the voluntary actions of the body such as movement of flight, and the ANS is responsible for the coordination of involuntary actions of the organs, intestines, blood vessels and glands. The primary function of the nervous system is to integrate the functions of the body.

Electrical stunning, using a water bath stunner, is the most common method employed to slaughter poultry under commercial conditions. The purpose of electrical stunning is to induce insensibility in order to perform humane neck cutting and to avoid recovery of consciousness and wing flapping during bleeding. The basic principle involved in electrical stunning is that an electrical current is passed through the brain to induce epilepsy. The occurrence of grand mal epilepsy is considered to be an indicator of the state of unconsciousness (based on the human analogy).

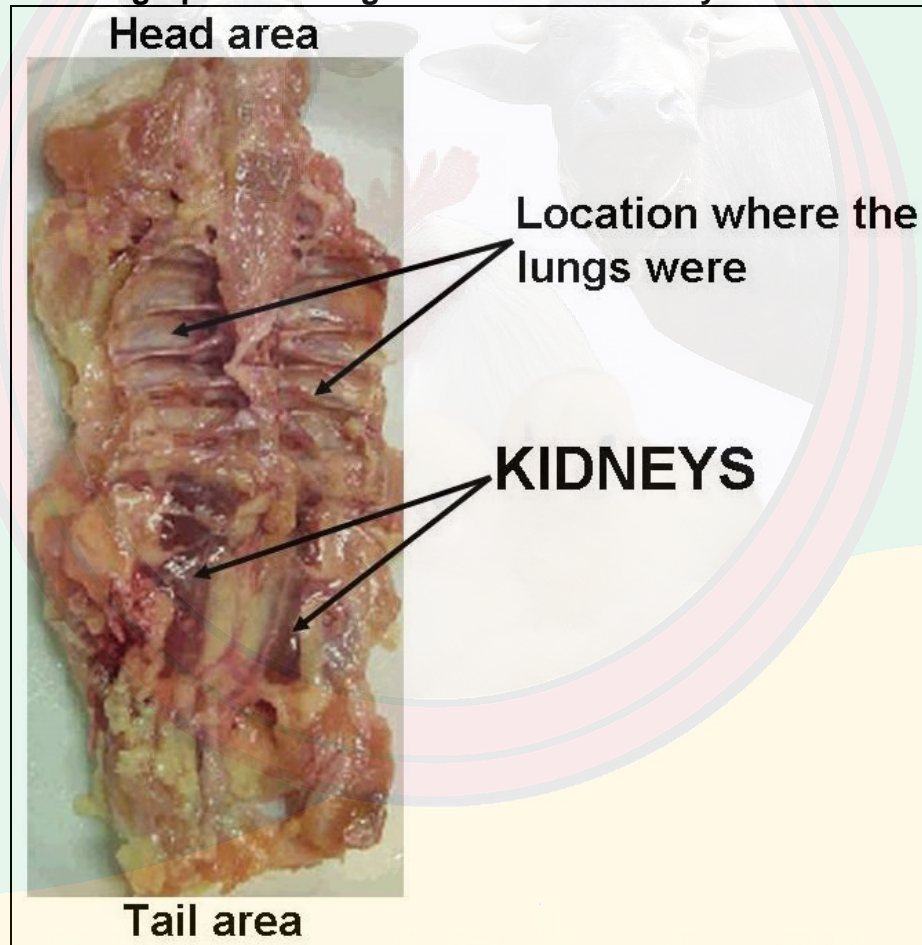
Controlled Atmosphere Killing (CAK) is an alternative method for slaughtering poultry. It involves placing the chickens in a container in which the atmosphere lacks oxygen and is made up of argon and/or nitrogen and/or CO₂. The result is that the chickens lose consciousness. Argon and nitrogen are important components of a painless gassing process as using CO₂ seems to cause distress. The respiratory system has CO₂ detectors and high levels of CO₂ will result in a fighting response in chickens – typically wing flapping – which can result in increased wing damage. There are no such receptors for argon or nitrogen.

I. Excretory system

The main organ of the excretory system is the **kidney**. The functional units of kidneys are **nephrons**. The functions of the excretory system are to excrete water and metabolic wastes and to regulate the acid-base balance of the bird's body.

The two kidneys of the domestic fowl each generally with three lobes are found immediately behind the lungs on each side of the vertebral column and closely associated with it (Figure 3.19). They are brownish in color and their consistency is such that they are easily damaged during their removal. The kidneys are normally left in when a broiler carcass is processed.

Figure 3.19 - Photograph indicating location of the kidneys in back of a chicken.



Each kidney is divided into three distinct lobes. Chickens do not have a bladder. Urine passes from the kidney, through the **ureters**, which then empty into the **cloaca**. Chicken urine consists of yellowish fluid with a white pasty substance largely made of uric acid. **Uric acid is the main product of nitrogen metabolism in birds** and is not water soluble; this is why solids make up part of the urine.

The straight and narrow **ureter** is a tube that leaves the medial border of each kidney and opens into the cloaca adjacent to the deferent duct of the male or the oviduct of the female.

The primary component of poultry waste is **uric acid**, the major end product of protein utilization. Uric acid is a white, pasty substance. Poultry waste is comprised of urine and feces (see Figure 3.4); these are not separate.

As indicated in the discussion on the Circulatory system, birds have retained the more 'primitive' renal portal system, a feature not found in mammals. The renal portal system allows blood from the back portion of the body to flow to the kidneys via the iliac veins. There is a valve that allows blood to either pass on to the kidneys where nitrogenous wastes are removed, or return directly to the heart via the renal veins. Because of this renal portal system, ***drugs injected into the leg muscles may be toxic to the kidneys; usually it is better to inject into the large muscles of the chest.***

Gout is a metabolic disorder associated with the kidneys. In gout the kidney function is slowed down to a point where uric acid accumulates in blood and body fluids. It can also lead to accumulation of white uric acid crystals in soft tissues of various organs. There are two types of gout – visceral and articular.

Visceral gout is a condition in which uric acid crystals are seen in soft tissues. The visceral form of gout is commonly found in broilers resulting in economic losses due to mortality and morbidity. The kidney damage can arise from infection with certain strains of Infectious Bronchitis, Avian Nephritis virus, exposure to some mycotoxins, or inadequate water intake. Residual toxic effects due to some of the disinfectants have also been reported.

Articular gout is a condition in which urate crystal deposits are seen in joints. This condition is rarely seen in broilers. Main causes are genetics and high protein diets.

J. Immune system

The avian immune system operates on the same general principles as the mammalian immune system. It is divided into two mechanisms – non-specific and specific.

Non-specific immune mechanism includes the inherent ways in which the chicken resists disease. This protective system is often not considered when designing a poultry health program. The non-specific mechanisms include:

- ***Genetic factors*** – Chicken strains have been developed which do not have the required receptors to allow many disease organisms to infect them. For example, some strains of chickens are genetically resistant to the lymphoid leukosis virus.
- ***Body temperature*** – The high body temperature of the chicken precludes many diseases. For example, blackleg disease and anthrax of cattle are not problems in poultry. If the body temperature of the chicken is lowered, however, the disease may occur.

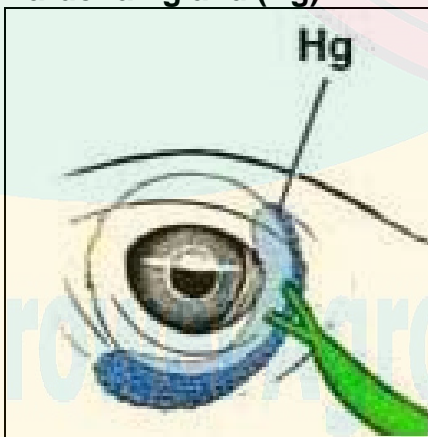
- **Anatomic features** – Many disease organisms cannot penetrate intact body coverings (**skin** and **mucous membranes**) or are trapped in the mucus secretions. Some nutritional deficiencies (biotin deficiency) or infectious diseases compromise the integrity of the body coverings, allowing penetration of disease organisms.
- **Normal microflora** – The skin and gut normally maintain a dense stable microbial population. This stable microflora prevents invading disease organisms from gaining a foothold. Improper use of antibiotics or poor sanitation can disrupt the balance of the microflora.
- **Respiratory tract cilia** – Parts of the respiratory system are lined with cilia which remove disease organisms and debris. If the air in the poultry house is of poor quality due to high levels of dust or ammonia, the ciliary system may be overwhelmed and become ineffective.

The reason that good management practices are important in maintaining poultry health is better understood when the non-specific immune mechanisms are defined. For example: the overuse of antibiotics or poor sanitation may lead to a disruption of the normal microflora; poor nutrition may lead to deficiencies which allow disease organisms to penetrate the protective body coverings; selection of disease resistant strains of chickens may preclude or lessen the effects of certain diseases; and others.

Specific immune mechanisms (acquired system) are characterized by specificity, heterogeneity, and memory. This system is divided into cellular and non-cellular (humoral) components.

The **non-cellular component** includes immunoglobulins (**antibodies**) and the cells which produce them. Antibodies are specific for the foreign material (**antigen**) to which they attach. For example, the antibody against Newcastle disease virus will attach only to the Newcastle virus, not to the infectious bronchitis virus.

Figure 3.20 - Location of the Harderian gland (Hg)



The cells which produce antibodies are called **B-lymphocytes**. These cells are produced in the embryonic liver, yolk sac and bone marrow. The cells move to the **Bursa of Fabricius (BF)** after 15 days of incubation through to about 10 weeks of age. The BF programs these cells which then move to the blood, spleen, cecal tonsils, bone marrow, **Harderian gland** (found in the eye socket, see Figure 3.20), and thymus. Destruction of the BF at a young age by Gumboro disease (also known as Infectious Bursal Disease, or IBD) or Marek's disease prevents programming of B-cells. Thus, the chicken will not be able to respond to diseases or vaccinations by producing antibodies.

The **cellular component** of the specific immune mechanisms includes all the cells that react with specificity to antigens, except those associated with antibody production. The cells associated with this system, the T-lymphocytes, begin as the same stem cells as

the B-cells. However, the T-lymphocytes are programmed in the thymus rather than the BF.

A chicken may become immune to a disease organism by producing antibodies itself or by obtaining antibodies from another animal. When the chicken produces its own antibodies following exposure to a foreign material, the process is called **active immunity**. This occurs after the bird is exposed to a vaccine or a field disease challenge. Active immunity is harmed by anything which damages the cellular or humoral immune systems. When the chick receives pre-made antibodies from the hen through the egg, this is termed **passive immunity**. These antibodies are not produced by the chick. Maternal antibodies are present in the yolk, albumin, and fluids of the egg. If the hen has a high antibody titer level to a disease, the chick should also be immune for several weeks. However, since the immune system of the chick is not stimulated, there will be no antibodies produced by the chick and no memory cells. The flock manager must be aware of the maternal antibody levels in the chicks to schedule vaccinations. If chickens are vaccinated when maternal antibody titer levels are elevated, the vaccine may be buffered excessively resulting in a reduced response. Conversely, if vaccinations are delayed and maternal titer levels are low, a severe vaccine reaction may result.



Growel
Commitment To Quality



Growel Agrovvet Private Limited
www.growelagrovvet.com